

# Rats from selected communities of Caraga Region, Philippines: Their helminths and potential role as indicators of *Schistosoma japonicum* transmission

Sheina Macy P. Manalo<sup>\*1,4</sup>, Billy P. Divina<sup>1,4</sup>, Philip P. Ocampo<sup>1</sup>, Moses Edric G. Abadilla<sup>2</sup>, Kim Louise A. Patagnan<sup>2</sup>, Leonardo A. Estaño<sup>3</sup>, Remil L. Galay<sup>1,4</sup>, and Vachel Gay V. Paller<sup>2,4</sup>

<sup>1</sup>Department of Veterinary Paraclinical Sciences, College of Veterinary Medicine, University of the Philippines, Los Baños, Laguna 4031 Philippines

<sup>2</sup>Parasitology Research Laboratory, Animal Biology Division, Institute of Biological Sciences, University of the Philippines, Los Baños, Laguna 4031 Philippines

<sup>3</sup>Department of Biological Sciences, College of Science and Mathematics, Mindanao State University-Iligan Institute of Technology, Iligan City, Lanao del Norte 9200 Philippines

<sup>4</sup>Zoonoses Center, University of the Philippines, Los Baños, Laguna 4031 Philippines

## ABSTRACT

Schistosomiasis is an endemic parasitic disease in the Philippines with reported high prevalence in the Caraga Region. As an agricultural region with abundant rice fields, there is a greater risk of infection because rice fields are favorable transmission environments for schistosomiasis. Rats, commonly present in these rice fields, are possible carriers of zoonotic diseases. This study aimed to describe zoonotic helminths in rats from seven municipalities of Agusan del Sur and Surigao del Norte. Rats were collected using cage traps placed in selected rice fields. Dissection of captured rats, tissue digestion, and coprological techniques were done to recover parasites. Locations of *S. japonicum*-positive rats were mapped with snail habitats and *S. japonicum*-positive households to assess possible transmission links. A high percentage of rats (94.6%) harbored helminths such as *Capillaria hepatica*, *Hymenolepis diminuta*, *Angiostrongylus cantonensis*, *Echinostoma* spp., *Taenia taeniaeformis*, *Raillietina* spp., *Artyfechinostomum malayanum*, *Aspicularis tetraptera*, *Trichuris* sp., *Syphacia* sp., *Physaloptera* sp., *Rictularia* spp., and *Nippostrongylus* sp. Among the 74 rats examined, 39.2% were positive for *S. japonicum* eggs, with higher occurrence in Agusan del Sur (51.1%). Spatial mapping revealed that most *S. japonicum*-positive rats were located near infected households and snail sites, thus highlighting their role as schistosomiasis sentinels for identifying areas of active *S. japonicum* transmission in the environment and the need for

integrated One Health approaches for schistosomiasis surveillance and intervention.

## INTRODUCTION

In the Philippines, wild rats are considered major pests because they cause both direct and indirect damage to property and crops, contaminate food and animal feeds, and act as carriers of several diseases (Cuaterno, 2008; Meerburg et al., 2009). Human infections involving rats may occur from bites, consumption of food products or water contaminated with rodent excreta, or through their ectoparasitic arthropod vectors. Rats also play an important role in maintaining pathogen transmission cycles in several environments, such as densely populated urban areas, rural areas and natural habitats (Himsworth et al., 2013). Zoonotic pathogens that have been reported in rats include helminths such as *Trichinella* spp., *Angiostrongylus cantonensis*, *Capillaria hepatica* (syn. *Callodium hepaticum*), *Hymenolepis* spp., *Raillietina* spp., *Fasciola* spp., *Paragonimus* sp., *Echinostoma* spp., and *Schistosoma* spp. (Eduardo et al., 2008; Himsworth et al., 2013). These parasites can cause morbidity in both humans and animals.

The zoonotic blood fluke, *S. japonicum*, remains endemic in many provinces of the Philippines. Approximately 12 million Filipinos are at risk and about 2.5 million individuals are directly exposed to the disease (Leonardo et al., 2016), making it a public health concern in the country. The Caraga region (Region 13) in

\*Corresponding author

Email Address: [smanalo@up.edu.ph](mailto:smanalo@up.edu.ph)

Date received: 15 October 2025

Dates revised: 27 January 2026, 11 April 2026

Date accepted: 21 April 2026

DOI: <https://doi.org/10.54645/2026191OTM-72>

## KEYWORDS

parasites, rats, schistosomiasis, zoonoses, Philippines

Mindanao has the highest reported human prevalence among other regions of the island of Mindanao (Leonardo et al., 2012).

Infection with *Schistosoma japonicum* occurs through contact with freshwater containing infective cercariae released by freshwater snails (intermediate host). After penetrating the skin, the parasite migrates and matures into adult schistosomes in the mesenteric veins, where the females release eggs. These eggs are excreted in the host's feces. Once in the water, they hatch into miracidia that will infect freshwater snails, thereby maintaining the transmission cycle (Ross and Yuesheng, 2016). Farmers are at greater risk since rice fields are known to be favorable locations for the transmission of *Schistosoma japonicum* (Yi-Xin and Manderson, 2005). The abundance of pest rats in these areas may be of concern as they may play a role in the pathogen transmission cycles.

There is still a lack of information about the helminth infection of rats in some areas of Mindanao, particularly the Caraga Region, which is abundant in rice fields near human habitations. Thus, the present study aimed to fill this knowledge gap by identifying helminth fauna of rats spicceis sampled from rice fields in the region and describe *S. japonicum* infection in rats. Increased knowledge of the presence of zoonotic parasites in these rodents can benefit public health by evidence-based implementation of the most appropriate control measures for this region and communities.

## MATERIALS AND METHODS

### Ethical statement

All protocols involved in the handling of rats in this study were approved by the Institutional Animal Care and Use Committee (IACUC) of the University of the Philippines Los Baños (UPLB) (Ref. No.: CAS-2018-020). A gratuitous permit (Ref No. R-13-2019-57) from the Department of Environment and Natural Resources in the Caraga Region (DENR-13) was obtained before rat trapping.

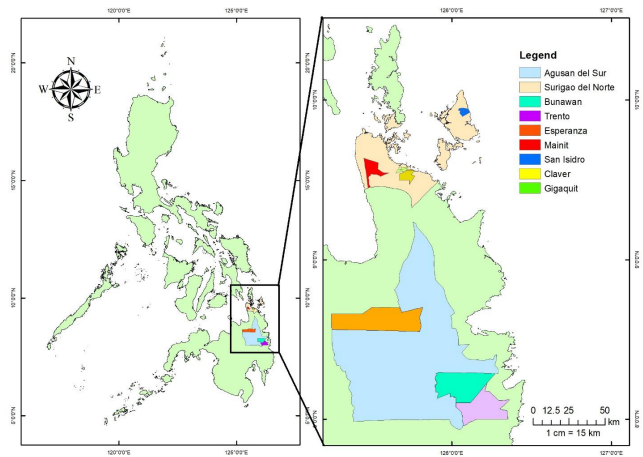
### Study area and sampling

In this study, seven municipalities were selected as sampling sites: namely the municipalities of Bunawan, Trento, and Esperanza of Agusan del Sur, and the municipalities of Mainit, Gigaquit, Claver (mainland) and San Isidro (island) of Surigao del Norte.

In these areas, rat traps were placed in rice fields near selected households from the concurrent study (Paller et al., 2025) between August 2019 and February 2021. Rectangular metal traps baited with fried fish were used (as previously described by Aplin et al., 2003).

The traps were placed in the evening, approximately 25 meters apart from each other and 100 meters away from the residential areas depending on local topography and then retrieved in the morning of the following day.

Captured rats were transported to the laboratory and humanely euthanized by cervical dislocation for smaller rats (<150 g) or intraperitoneal overdose of pentobarbital sodium (Doletal®, Vetoquinol UK Ltd.) dosed at 200mg/kg (Close et al., 1996) for larger rats.



**Figure 1:** Map illustrating the study sites where rat samples were collected in Caraga Region, Mindanao.

### Rat Species identification

All captured rats (n=74) were humanely euthanized by a licensed veterinarian through the method approved by UPLB IACUC and in accordance with the guidelines of Department of Agriculture-Bureau of Animal Industry, Administrative Order No. 40-99 (1999). Morphometrics such as sex, weight, total body length (TBL), fur color, and other details such as place of collection were recorded. Rat species were identified using the Synopsis of Philippine Mammals by Heaney et al. (2010) as a reference and with the aid of a rodent expert in UPLB.

### Animal dissection

Dissection of rats was done according to the protocol (as described by Aplin et al., 2003; Herbreteau et al., 2011; Parsons et al., 2016). Briefly, the animal was placed on its ventral side on the dissecting tray, limbs fixed with dissecting pins. The skin of the lower part of the abdomen was lifted using forceps and was cut using scissors, extending the cut through the skin and abdominal musculature until the abdominal contents were exposed. Next, rectum was tied off and cut above the tie. The gastrointestinal tract (GIT) was separated from the abdominal cavity and placed in a sealable container with 95% ethanol. The liver was separated from the GIT and placed in a sealable plastic bag. The lungs and heart were separated from the thoracic cavity and were placed in separate sealable plastic bags. Lungs, heart, and liver were frozen (-20 °C) prior to transport. The collected visceral organs were then transported to the laboratory for further parasitological examination.

### Harvest of Parasites and Identification

The GIT, heart, lungs, and liver of the rat were examined for adult worms, however, vascular perfusion of the mesenteric and portal veins was not done prior to organ dissection. Collected worms were preserved in 100% ethanol for intended molecular analyses. Additionally, the heart, lungs, and liver, which are other known predilection sites of parasites in rats, were artificially digested separately with pepsin-HCl solution with a magnetic stirrer on a hot plate at 37°C for one hour. Digested samples were filtered using 1 mm stainless steel mesh sieve and placed in a petri dish for microscopic examination of larvae. A portion of the intestinal content was collected and transferred into a test tube. Normal saline was added, stirred, and filtered using a 125 µm stainless steel mesh sieve. The filtrate was then centrifuged at 1500 rpm for 5 minutes and supernatant was discarded. A drop of the sediment was then placed on a slide. Slides were examined at 100× and 400× magnification for parasite ova identification (Zajac and Conboy, 2021) Ova and larvae were identified by comparing their sizes and morphological features as previously described by Yamaguti (1958; 1959; 1961) and Eduardo et al. (2008).

### Mapping of sites

The GPS locations were collected during collection of trapped rats using handheld GPS (Garmin eTREX 20). Secondary data on *S. japonicum*-positive snail sites were obtained from the Department of Health (unpublished data). These data were derived from routine, risk-based malacological surveillance conducted under the national Schistosomiasis Control and Elimination Program. Household-positive sites were obtained from a concurrent study of Paller et al. (2024), wherein both human and animals in the households were tested for *S. japonicum* using Kato-Katz, sedimentation, and flotation techniques.

### Statistical analysis

All analyses were performed using statistical software (StataCorp, 2019). Frequencies and occurrence of *S. japonicum* infection and other helminths were computed per municipality, sex, and species. Fisher's Exact Test at 5% significance level was used to test differences among variables.

## RESULTS AND DISCUSSION

A total of 74 rat samples were collected and examined, in which four (4) rat species were observed, namely: *Rattus tanezumi*, *R. argentiventer*, *R. norvegicus* and *R. exulans* (Table 1).

**Table 1:** Number of rat samples collected from selected study sites in Caraga Region, Mindanao, Philippines.

Rat Species	Study Sites		Total
	Agusan del Sur	Surigao del Norte	
<i>R. argentiventer</i>	10	7	17
<i>R. exulans</i>	10	2	12
<i>R. norvegicus</i>	2	4	6
<i>R. tanezumi</i>	26	13	39
<b>Total</b>	<b>48</b>	<b>26</b>	<b>=74</b>

Initial laboratory analysis revealed that trematodes, cestodes, and nematodes infected rats. Among the 74 rats examined, 70 (94.6%) were infected with parasites, in which 14 species of helminths were observed, namely: *Capillaria hepatica*, *Hymenolepis diminuta*, *Schistosoma japonicum*, *Angiostrongylus cantonensis*, *Echinostoma* spp., *Trichuris* spp., *Taenia taeniaeformis*, *Raillietina* spp., *Artyfechinostomum malayanum*, *Aspicularis tetraptera*, *Physaloptera* sp., *Syphacia* sp., *Rictularia* sp., and *Nippostrongylus* sp. (Table 2), which were also detected in different species of rats in some areas of the Philippines (Jueco and Sabala, 1990; Eduardo et al., 2008; Florague et al., 2009; Carabin et al., 2015; Tujan et al., 2016; Claveria, 2017). This overlap demonstrates that the diversity of rodent-borne helminths observed in the region does not differ from previous findings across the

country, and that rats are significant reservoirs and hosts of these parasitic infections. Other helminth species detected in rats in other parts of the Philippines, which were not detected in this study, include *Capillaria gastrica*, *Anatrichosoma* sp., *Filaroides* sp., *Globocephalus* sp., *Gongylonema neoplasticum*, *Hepatojarakus malayae*, *Heterakis spumosa*, *Protospirura muricola*, *Rictularia tani*, *Squamaneia* sp., *Syphacia muris*, *Trichosomoides crassicauda*, *Euparyphium* spp., *Plagiorchis* spp., *Strongyloides* sp., and *Paragonimus westermani*. (Jueco and Sabala, 1990; Eduardo et al., 2008; Florague et al., 2009; Carabin et al. 2015, Claveria, 2017)

**Table 2:** Helminth parasites recovered from captured rats (n=74) from selected municipalities of Caraga region, Philippines

Helminth Species	Parasite Stage	Organ Location	Occurrence (%)
<b>Trematode</b>			
<i>Schistosoma japonicum</i>	Ova	Liver Lungs	39.19
<i>Echinostoma</i> spp.	Adult	Small intestine	12.20
<i>Artyfechinostomum malayanum</i>	Adult	Small intestine	1.35
<b>Cestode</b>			
<i>Hymenolepis</i> spp.	Adult & Egg	Small intestine	22.97
<i>Taenia taeniaeformis</i> (strobilocercus fasciolaris)	Larva/Metacestode	Liver	20.27
<i>Raillietina</i> spp.	Adult	Small intestine	6.76
<b>Nematode</b>			
<i>Angiostrongylus cantonensis</i>	Larvae (L1) / Adult	Lung	58.11

<i>Calodium hepaticum</i> (= <i>Capillaria hepatica</i> )	Ova	Liver	12.16
<i>Nippostrongylus</i> sp.	Adult	Small intestine	12.16
<i>Trichuris</i> sp.	Ova	Small intestines	9.46
<i>Syphacia</i> sp.	Adult	Small intestine	6.76
<i>Physaloptera</i> sp.	Adult	Stomach	1.35
<i>Rictularia</i> sp.	Adult	Small intestines	1.35
<i>Aspicularis tetrapetra</i>	Adult	Small intestines	1.35

High parasitism (57.7-100%) in captured rats was also observed in previous studies in some areas of the Philippines and neighboring southeast Asian countries (Namue and Wongsawad, 1997; Chasiri et al., 2012; Mohd Zain et al., 2012; Ribas et al., 2016; Claveria, 2017; Chasiri et al., 2017). Thirteen (13) species of helminths were identified which were also reported in several related studies across the country (Jueco and Zabala, 1990; Claveria et al., 2005; Eduardo et al., 2008; Claveria, 2017; Quilla and Paller, 2020). In this study, all captured *R. argentiventer* species were positive for helminth infection, indicating a high infection rate in this species. However, *R. tanezumi* species was found to have a more diverse helminth fauna. A study conducted by Chaisiri et al. (2015) on wild-caught murid rodents (forest, non-flooded land, irrigated land, and human settlements in seven localities of Thailand, Cambodia, and Lao PDR) has identified that *R. tanezumi* plays a central role as a reservoir of zoonotic helminths. However, in this study, no significant statistical association ( $p > 0.05$ ) between species, sex, and helminth infection in rat hosts was observed, likely due to the small sample size.

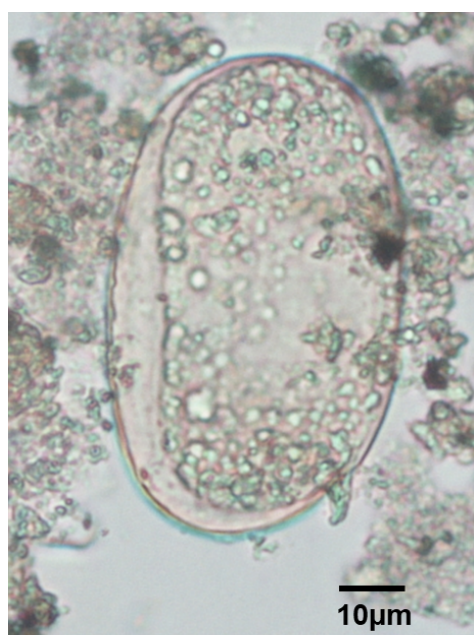
In this study, it was observed that *A. cantonensis*, *S. japonicum*, and *Hymenolepis* spp. were the parasites that occurred the most (Table 2). These parasites are zoonotic and therefore pose risks to human health. *A. cantonensis* is the major cause of eosinophilic meningitis in humans (Lv et al., 2017). Occurrences of *A. cantonensis* have also been reported in rats and snails in the northern island of the Philippines, Luzon (Castillo and Paller, 2018; Estaño et al., 2021) and in rats from southern islands in the Philippines, Mindanao (Estaño, 2023), suggesting endemic transmission not only in Luzon islands but also in Mindanao, where rats from this study were collected. Humans can be infected with *H. diminuta* by ingestion of infected arthropods containing cysticercoids, although cases for both zoonotic diseases are uncommon. Since human cases from the Philippines have been reported (Riley and Shannon, 1922; de Leon, 2004; Lammers et al., 2015), it is still of public health concern and warrants continued surveillance as these mentioned zoonotic parasitic diseases might be underdiagnosed (Khamsai et al., 2022; Mijatović et al., 2024).

*Schistosoma japonicum* eggs were recovered from the livers of 29 rats (39.19%). The absence of recovered adult *S. japonicum* worms may be attributed to the omission of vascular perfusion prior to ethanol preservation of organs and dissection, the ethanol preservation applied in the study, and the possible low adult worm burden typically observed in less-permissive hosts such as rats (He et al., 2001), making egg detection a more reliable indicator of infection. It was noted that rats from municipalities of Agusan del Sur had higher *S. japonicum* infection, however, no statistically significant difference between *S. japonicum* occurrence and location was observed, likely due to sample size collected from that location (Table 3). A study by Leonardo et al. (2008) reported that the province of Agusan del Sur has the highest prevalence of schistosomiasis japonicum in humans (3.95%). In this study, rats in municipalities from Agusan del Sur showed higher occurrence of *S. japonicum* than those in Surigao del Norte, indicating that

there is high transmission of *S. japonicum* not only to humans, but also to other mammalian hosts in the rice fields of Agusan del Sur.

**Table 3:** Occurrence of *S. japonicum* based on species, location, and sex of rats (n=74) from selected municipalities of Caraga Region, Philippines.

	Occurrence	p-value
<b>Rat Species</b>		
<i>Rattus argentiventer</i> (n=17)	4 (23.53%)	0.16
<i>Rattus norvegicus</i> (n=6)	1 (16.67%)	
<i>Rattus tanezumi</i> (n=39)	20 (51.28%)	
<i>Rattus exulans</i> (n=12)	4 (33.33%)	
<b>Location</b>		
Bunawan (n=9)	2 (22.22%)	0.19
Claver (n=8)	1 (12.50%)	
Esperanza (n=35)	18 (51.43%)	
Gigaquit (n=5)	1 (20.00%)	
Mainit (n=6)	2 (33.33%)	
San Isidro (n=7)	2 (28.57%)	
Trento (n=4)	3 (75.00%)	
<b>Sex</b>		
Female (n=28)	11 (39.29%)	1.00
Male (n=46)	18 (39.13%)	

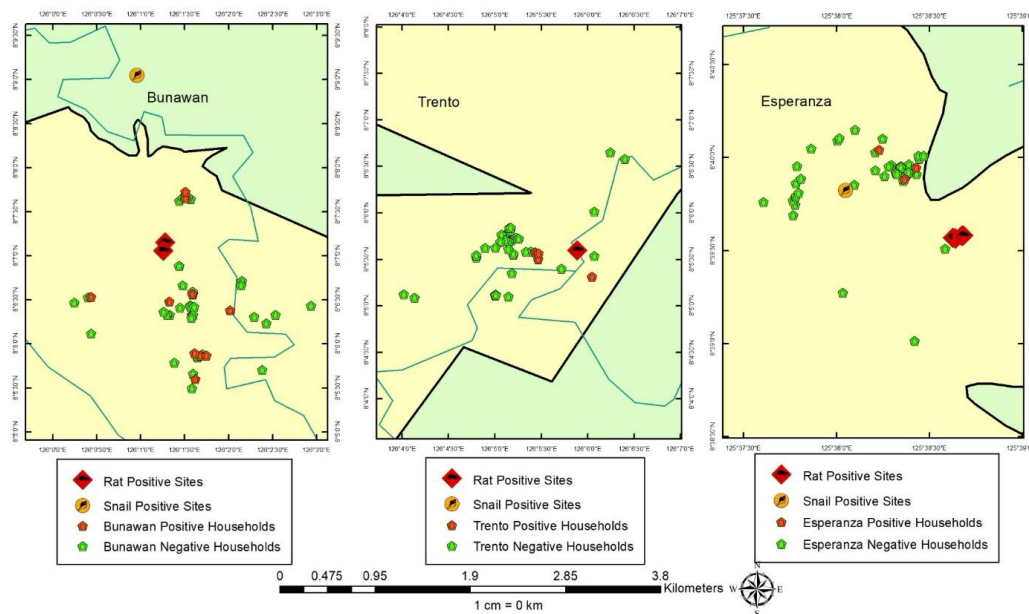


**Figure 2:** Representative microphotograph of *Schistosoma japonicum* egg (79.06µm × 47.06µm) recovered from digested liver sample of *Rattus tanezumi* (40×)

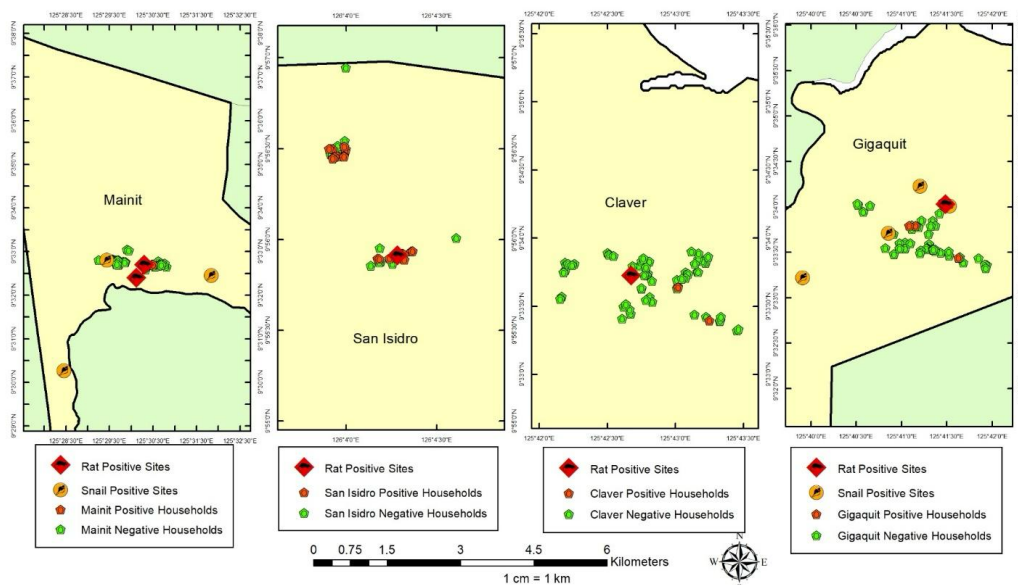
Maps of the capture locations of *S. japonicum*-positive rats, snail, and household sites illustrated possible transmission sites for infection (Figures 3-4). In the maps of Agusan del Sur, it was observed that *S. japonicum*-positive households were in close proximity with the “sites with *S. japonicum*-positive rats and nearby *S. japonicum*-positive snail habitats (Figure 3). It was noted that in Trento, no snail-positive sites were documented or identified by the surveillance program. As for the municipalities of Surigao del Norte, *S. japonicum*-positive households in Mainit and San Isidro were near the rat-positive sites, while in Gigaquit, rat-positive sites were near snail-positive sites (Figure 4). The role of rats in the transmission of *S. japonicum* infection may vary from one endemic region to another. Rudge et al. (2008) have described in their study in Samar province, Luzon Islands, Philippines, that rat infection may be weakly associated with human infection and suggested that rats are good indicators of the presence of the snail vectors, but may not share with humans the same strain of *S. japonicum*. However, the presence of a sizable population of *S. japonicum*-infected field rats

in endemic areas might still pose a risk to public health. Other studies in the Philippines, particularly in Samar, have suggested that rats may play an important role in the transmission of *S. japonicum* in endemic villages (Fernandez, et al., 2007; Riley et al., 2008; Carabin et al., 2015).

A recent review by Tabilin et al. (2025) further discussed the epidemiological role of rats in *S. japonicum* transmission, although rats are considered non-permissive hosts due to their limited capability to produce viable schistosome eggs because of their biology, findings from transmission models have demonstrated associations between rodent and human infections. This may be evidenced by this study’s findings where most *S. japonicum*-positive rats were located near *S. japonicum*-positive households. However, schistosomiasis transmission in rats may still vary depending on ecological conditions in endemic areas in the Philippines.



**Figure 3:** Maps showing *Schistosoma*-positive rats in relation to snail and household *Schistosoma*-positive sites in selected municipalities of Agusan del Sur, Caraga Region, Philippines.



**Figure 4:** Maps showing *Schistosoma*-positive rats in relation to snail and household *Schistosoma*-positive sites in selected municipalities of Surigao del Norte, Caraga Region, Philippines.

Rodents can be considered as important schistosomiasis sentinels for identifying areas of transmission in the environment. The findings of this study provide field-based evidence of this, as most *S. japonicum*-positive rats were near *S. japonicum*-positive households and snail habitats. Rodent infection data can help identify potential *S. japonicum* environmental exposure hotspots and inform more targeted surveillance and control strategies. Rodents may also serve as complementary indicators of active transmission areas, especially in cases where malacological data may be limited.

## CONCLUSION

This study provides field-based evidence that rats can serve as useful sentinels for identifying schistosomiasis transmission hotspots in the environment. The close spatial association between *S. japonicum*-infected rats, positive households, and documented snail habitats indicates that rodent infections reflect active transmission areas. Surveillance of zoonotic parasites in local rodent populations can be beneficial to determine sources of environmental contamination and parasite transmission in a particular endemic area. And design more focused surveillance efforts and control strategies specific to local communities. A One-Health approach in the control of schistosomiasis is highly recommended. Further molecular studies to identify genetic similarities of parasites between humans and rats are recommended to further understand their role in the maintenance of the parasite life cycle and transmission.

## ACKNOWLEDGMENTS

This work was supported by the Department of Science and Technology (DOST) - Philippine Council for Health Research and Development (PCHRD).

## CONFLICT OF INTEREST

The authors declare no competing interests.

## CONTRIBUTIONS OF INDIVIDUAL AUTHORS

**Sheina Macy P. Manalo:** Methodology, Investigation, Formal Analysis, Writing–Original Draft; **Billy P. Divina:** Conceptualization, Methodology, Formal Analysis; **Philip P. Ocampo:** Investigation, Writing–Original Draft; **Moses Edric G. Abadilla:** Investigation, Writing–review and editing; **Kim Louise A. Patagnan:** Investigation, Visualization; **Leonardo A. Estaño:** Investigation, Formal Analysis; **Remil L. Galay:** Writing–review and editing; **Vachel Gay V. Paller:** Conceptualization, Writing–review and editing

## REFERENCES

Aplin K, Brown P, Jacob J, Krebs C, Singleton G. Field methods for rodent studies in Asia and the Indo-Pacific. Canberra, Australia: ACIAR, 2003. 223 p.

Bureau of Animal Industry. Rules and regulations on the conduct of scientific procedures using animals. BAI Administrative Order No. 40-99 1999; August 2

Carabin H, McGarvey ST, Sahlu I, Tarafder MR, Joseph L, De Andrade, BB, Balolong, E, Olveda, R. *Schistosoma japonicum* in Samar, the Philippines: infection in dogs and rats as a possible risk factor for human infection. *Epidemiol Infect* 2015; 143: 1767–1776. <https://doi.org/10.1017/S0950268814002581>

Castillo DSC, Paller VGV. Occurrence of *Angiostrongylus cantonensis* in rodents from the rice granary of the Philippines and associated risk factors for zoonotic transmission. *J Parasit Dis* 2018; 42: 350–356. <https://doi.org/10.1007/s12639-018-1005-z>

Chaisiri K, Chaeychomsri W, Siruntawinetti J, Ribas A, Herbreteau V, Morand, S. Diversity of gastrointestinal helminths among murid rodents from northern and northeastern Thailand. *Southeast Asian J Trop Med Public Health* 2012; 43: 21–28.

Chaisiri K, Chou M, Siew CC, Morand S, Ribas A. Gastrointestinal helminth fauna of rodents from Cambodia: emphasizing the community ecology of host–parasite associations. *J Helminthol* 2017; 91: 726–738.

Chaisiri K, Siribat P, Ribas A, Morand S. Potentially zoonotic helminthiases of murid rodents from the Indo-Chinese Peninsula: impact of habitat and the risk of human infection. *Vector Borne Zoonotic Dis* 2015; 15: 73–85.

Claveria FG. Parasites bared in *Rattus norvegicus* and *Rattus tanezumi*. *Asian J Agri & Biol* 2017; 5: 151–157.

Close B, Banister K, Baumans V, Bernoth EM, Bromage N, Bunyan J, Erhardt W, Flecknell P, Gregory N, Hackbarth H, Morton D. Recommendations for euthanasia of experimental animals: Part 2. *ScienceGg*. 1997;31(1):1–32.

Cuaterno WR. Economic impacts and management of pest rodents: a national perspective. In: Singleton GR, Joshi RC, Sebastian LS, eds. *Philippine Rats: Ecology & Managements*. Science City of Muñoz, Nueva Ecija: Philippine Rice Research Institute, 2008.

de Leon WU. *Hymenolepis diminuta*. In: Belizario VY, Solon JAA, eds. *Philippine Textbook of Medical Parasitology*. 2nd ed. Manila: University of the Philippines Press, 2004:176–177.

Dumag PU, Gajudo CE, Sena CY, Cardenas EC, Fementira EB. Epidemiology of animal schistosomiasis in the Philippines. *Philipp J Anim Ind* 1981; 36.

Eduardo SL, Domingo CYJ, Divina BP. Zoonotic parasites of rats in the Philippines. In: Singleton GR, Joshi RC, Sebastian LS, eds. *Philippine Rats: Ecology & Managements*. Science City of Muñoz, Nueva Ecija: Philippine Rice Research Institute, 2008.

Environmental Systems Research Institute. ArcGIS Online 2021 [Web application]. <https://www.arcgis.com>

Estaño LA. Prevalence of *Angiostrongylus cantonensis* in definitive and intermediate hosts collected from agricultural areas in Ampayon, Butuan City, Southern Philippines. *J Parasit Dis* 2023; 47: 807–814. 814. <https://doi.org/10.1007/s12639-023-01626-2>

Estaño LA, Bordado AMD, Paller VGV. *Angiostrongylus cantonensis* infection of non-native rats in Mount Makiling Forest Reserve, the Philippines. *Parasitology* 2021; 148: 143–148. <https://doi.org/10.1017/S0031182020001511>

Fernandez TJ, Tarafder MR, Balolong E, Joseph L, Willingham AL, et al. Prevalence of *Schistosoma japonicum* infection among animals in fifty villages of Samar Province, the Philippines. *Vector Borne Zoonotic Dis* 2007; 7: 147–155. <https://doi.org/10.1089/vbz.2006.0565>

Florague M, Joshi R, Sebastian L, Marquez L, Duque U, Domingo C. Endo- and ectoparasites of the Philippine rice field rat, *Rattus tanezumi* Temminck, on PhilRice farms. *Int Rice Res Notes* 2009; 31. <https://doi.org/10.3860/irrn.v31i1.1188>

- He YX, Salafsky B, Ramaswamy K. Host–parasite relationships of *Schistosoma japonicum* in mammalian hosts. *Trends Parasitol* 2001; 17: 320–324. [https://doi.org/10.1016/s1471-4922\(01\)01904-3](https://doi.org/10.1016/s1471-4922(01)01904-3)
- Heaney LR, Dolar ML, Balette DS, Esselstyn JA, Rickart EA, Sedlock, JL. Synopsis of Philippine mammals. Available: [http://archive.fieldmuseum.org/philippine\\_mammals/index.html](http://archive.fieldmuseum.org/philippine_mammals/index.html). Accessed 11 August 2021.
- Herbreteau V, Jittapalpong S, Rerkamnuaychoke W, Chaval Y, Cosson JF, Morand, S., eds. Protocols for Field and Laboratory Rodent Studies. Thailand: CERoPath, 2006. Available: [http://www.ceropath.org/FichiersComplementaires/Herbreteau\\_Rodents\\_protocols\\_2011.pdf](http://www.ceropath.org/FichiersComplementaires/Herbreteau_Rodents_protocols_2011.pdf). Accessed 15 January 2020
- Himsworth CG, Parsons KL, Jardine C, Patrick DM. Rats, cities, people, and pathogens: a systematic review and narrative synthesis of literature regarding the ecology of rat-associated zoonoses in urban centers. *Vector Borne Zoonotic Dis* 2013; 13: 349–359. <https://doi.org/10.1089/vbz.2012.1195>
- Jueco NL, Zabala ZR. The nematodes of *Rattus norvegicus* and *Rattus rattus mindanensis*. *Philipp J Vet Med* 1990; 27: 39–46.
- Khamsai S, Chotmongkol V, Tiamkao S, Maleewong W, Limpawattana P, Boonsawat, W, Sawunyavisuth, B, Aekphachaisawat, N, Sawanyawisuth, K. Eosinophilic meningitis epidemiological data from a national database in Thailand’s Department of Disease Control: a pragmatic, retrospective analytical study. *Orphanet J Rare Dis* 2022; 17: 393. <https://doi.org/10.1186/s13023-022-02532-1>.
- Lammers AJJ, Goorhuis A, van de Beek D, Grobusch MP, Bart A, van Gool, T, van Vugt, M. Eosinophilia à deux: a brain nagging souvenir from the Philippines. *Infection* 2015; 43: 615–617. Available: <https://doi.org/10.1007/s15010-015-0785-7>
- Leonardo L, Chigusa Y, Kikuchi M, Kato-Hayashi N, Kawazu S, Angeles, JM, Fontanilla, IK, Tabios, IK, Moendeg, K, Goto, Y, Fornillos, RJ, Chua, JC. Schistosomiasis in the Philippines: challenges and some successes in control. *Southeast Asian J Trop Med Public Health* 2016; 47: 651–666. <https://doi.org/10.1155/2012/936128>
- Leonardo LR, Rivera P, Saniel O, Villacorte E, Crisostomo B, Hernandez, L, Baquilod, M, Erce, E, Martinez, R, Velayudhan, R. Prevalence survey of schistosomiasis in Mindanao and the Visayas, the Philippines. *Parasitol Int* 2008; 57: 246–251. <https://doi.org/10.1016/j.parint.2008.04.006>
- Leonardo LR, Rivera P, Saniel O, Villacorte E, Leaban MA, Crisostomo B, Hernandez, L, Baquilod, M, Erce, E, Martinez, R, Velayudhan, R. A national baseline prevalence survey of schistosomiasis in the Philippines using stratified two-step systematic cluster sampling design. *J Trop Med* 2012; 2012: 936128. <https://doi.org/10.1155/2012/936128>
- Lv S, Zhou XN, Andrews JR. Eosinophilic meningitis caused by *Angiostrongylus cantonensis*. *ACS Chem Neurosci* 2017; 8: 1815–1816. <https://doi.org/10.1021/acschemneuro.7b00233>
- Meerburg BG, Singleton GR, Kijlstra A. Rodent-borne diseases and their risks for public health. *Crit Rev Microbiol* 2009; 35: 221–270. <https://doi.org/10.1080/10408410902989837>
- Mijatović S, Štajner T, Čalovski IČ, Dubljanin E, Bobić B, et al. Human infections by *Hymenolepis diminuta* in Europe: a case report and literature review. *Trans R Soc Trop Med Hyg* 2024; 118: 580–588. <https://doi.org/10.1093/trstmh/trae037>
- Mohd Zain SN, Behnke JM, Lewis JW. Helminth communities from two urban rat populations in Kuala Lumpur, Malaysia. *Parasites Vectors* 2012; 5: 47. <https://doi.org/10.1186/1756-3305-5-47>
- Namue C, Wongsawad C. A survey of helminth infection in rats (*Rattus* spp) from Chiang Mai Moat. *Southeast Asian J Trop Med Public Health* 1997; 28(Suppl 1): 179–183.
- Parsons MH, Sarno RJ, Deutsch MA. A detailed protocol to enable safe handling, preemptive detection, and systematic surveillance of rat-vectored pathogens in the urban environment. *Front Public Health* 2016; 4: 132. <https://www.ncbi.nlm.nih.gov/pmc/articles/PMC4945852/>. Accessed 17 June 2025.
- Quilla MHDP, Paller VGV. Histopathological features and prevalence of *Capillaria hepatica* infection in *Rattus* spp. in Philippine Mount Makiling forest reserve and its adjacent areas. *J Parasit Dis* 2020; 44: 338–348. <https://doi.org/10.1007/s12639-019-01189-1>
- Ribas A, Saijuntha W, Agatsuma T, Thongjun C, Lamsan K, Poonlaphdecha, S. Helminths in rodents from wet markets in Thailand. *Vector Borne Zoonotic Dis* 2016; 16(8): 537–40. <https://doi.org/10.1089/vbz.2015.1894>
- Riley S, Carabin H, Bélisle P, Joseph L, Tallo V, Balolong, E, Willingham, AL, Fernandez, TJ, Gonzales, RO, Olveda, R, McGarvey, ST. Multi-host transmission dynamics of *Schistosoma japonicum* in Samar Province, the Philippines. *PLOS Med* 2008; 5: e18. <https://doi.org/10.1371/journal.pmed.0050018>
- Riley WA, Shannon WR. The rat tapeworm, *Hymenolepis diminuta*, in man. *J Parasitol* 1922; 8: 109–117. <https://doi.org/10.2307/3270923>
- Ross AG, Yuesheng L. Life cycles of schistosomiasis. In: Jamieson BG, ed. *Schistosoma: Biology, Pathology and Control*. 1st ed. Boca Raton: CRC Press; 2016:34–37.
- Rudge JW, Carabin H, Balolong E Jr, Tallo V, Shrivastava J, Lu, DB, Basáñez, MG, Olveda, R, McGarvey, ST, Webster, JP. Population genetics of *Schistosoma japonicum* within the Philippines suggest high levels of transmission between humans and dogs. *PLOS Negl Trop Dis* 2008; 2: e340. <https://doi.org/10.1371/journal.pntd.0000340>
- StataCorp. Stata Statistical Software: Release 16 [software] 2019. StataCorp LLC. <https://www.stata.com>
- Tabilin EJ, Gray DJ, Jiz MA, Mationg ML, Inobaya M, Avenido-Cervantes, E, Sato, MO Sako, Y, Mu, Y, You, H, Kelly, M, Cai, P, Gordon, CA. Schistosomiasis in the Philippines: a comprehensive review of epidemiology and current control. *Trop Med Infect Dis* 2025; 10: 29. <https://doi.org/10.3390/tropicalmed10020029>
- Tujan MAA, Fontanilla IKC, Paller VGV. Vectors and spatial patterns of *Angiostrongylus cantonensis* in selected rice-farming villages of Muñoz, Nueva Ecija, Philippines. *J Parasitol Res* 2016; 2016: 3085639. <https://doi.org/10.1155/2016/3085639>
- Yamaguti S. *Systema Helminthum*: Vol. I. The Digenetic Trematodes of Vertebrates (in 2 parts). New York, NY: Interscience Publishers; 1958. 1575 p.

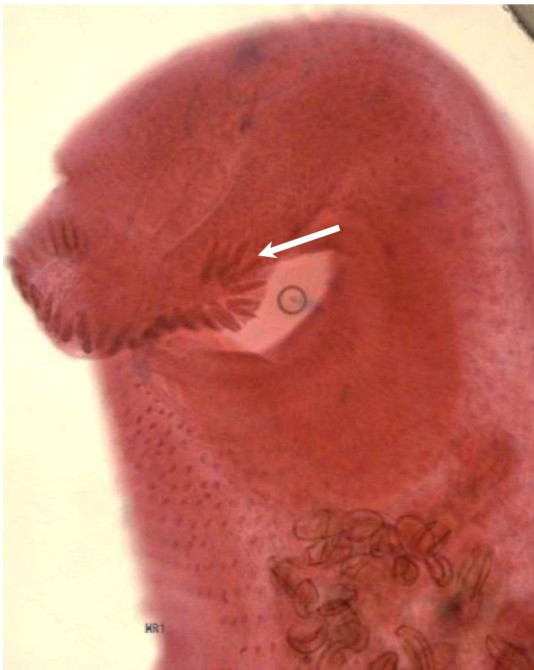Yamaguti S. *Systema Helminthum: Vol. II. The Cestodes of Vertebrates*. New York, NY: Interscience Publishers; 1959. 860 p.

Yamaguti S. *Systema Helminthum: Vol. III. The Nematodes of Vertebrates (in 2 parts)*. New York, NY: Interscience Publishers; 1961. 1261 p.

Yi-Xin H, Manderson L. The social and economic context and determinants of schistosomiasis japonica. *Acta Trop* 2005; 96: 223–231. <https://doi.org/10.1016/j.actatropica.2005.07.015>

Zajac AM, Conboy GA, eds. *Veterinary Clinical Parasitology*. 8th ed. Hoboken, NJ: Wiley-Blackwell; 2012. 368 p.

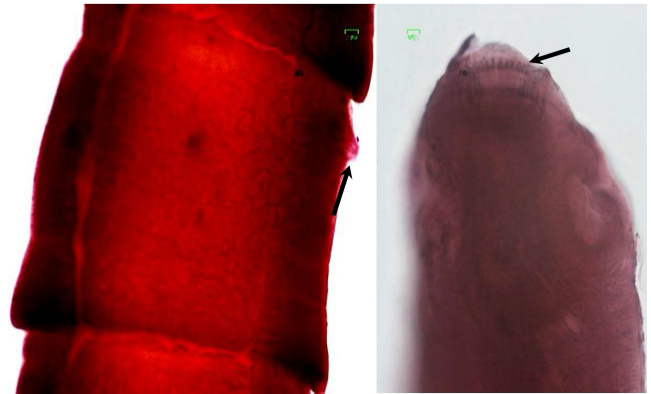
**APPENDIX**



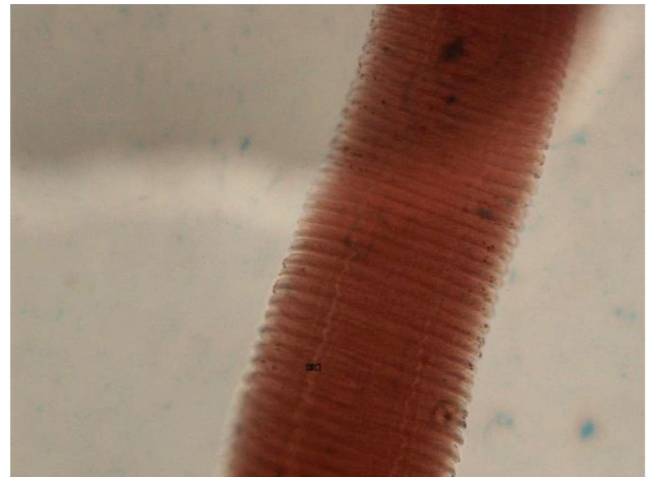
**Figure 5:** Representative microphotograph of the anterior region of *Euparyphium (=Echinostoma) ilocanum* from *Rattus argentiventer*, *R. norvegicus*, and *R. tanezumi* (Aceto-carmine stain, 400x). Note the presence of collar spines around the oral suckers (white arrow).



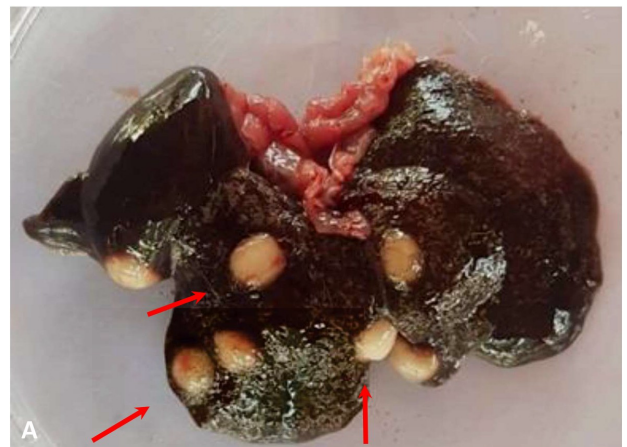**Figure 6:** Microphotograph of the anterior region of a single specimen of *Artyfechinostomum malayanum* from *Rattus argentiventer*. Head collar is not in focus but the cirrus sac (pointed) extends posterior to the ventral sucker (acetabulum) (Aceto-carmine stain, 400x).



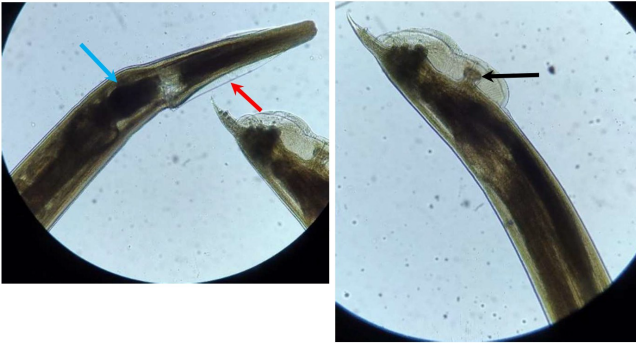
**Figure 7:** Gravid proglottid of *Raillietina garrisoni*, from *R. norvegicus*. Note the location of the genital pore in the anterior margin (pointed) (left) and the armed rostellum (pointed) (right) (Aceto-carmine stain, 40x).



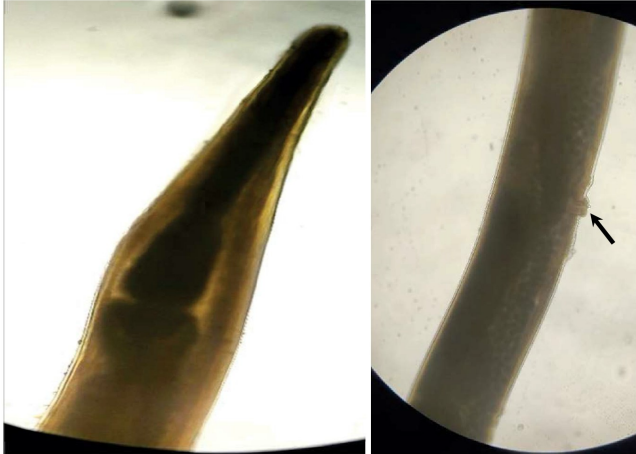
**Figure 8:** Representative microphotograph of *Hymenolepis* spp. immature proglottids from *Rattus argentiventer*, *R. norvegicus*, and *R. tanezumi* (Aceto-carmine stain, 400x).



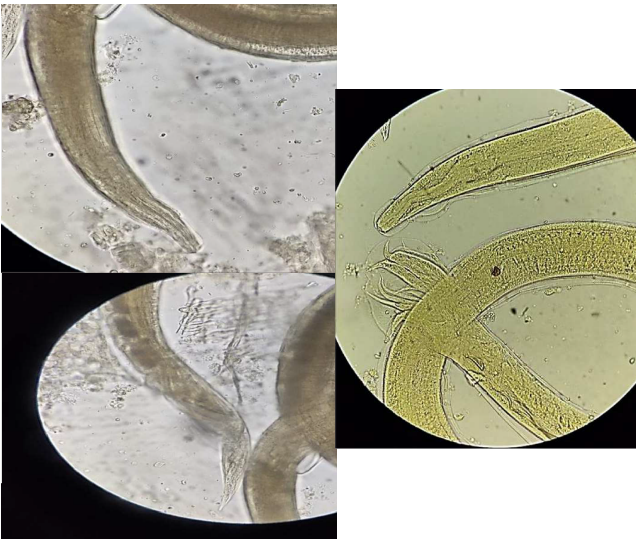
**Figure 9:** Representative gross photograph (A) of whole rat liver with multiple *strobilocercus fasciolaris* (some are pointed), the metacestode or cyst of the cat tapeworm, *Taenia taeniaformis* and an isolated cyst (B).



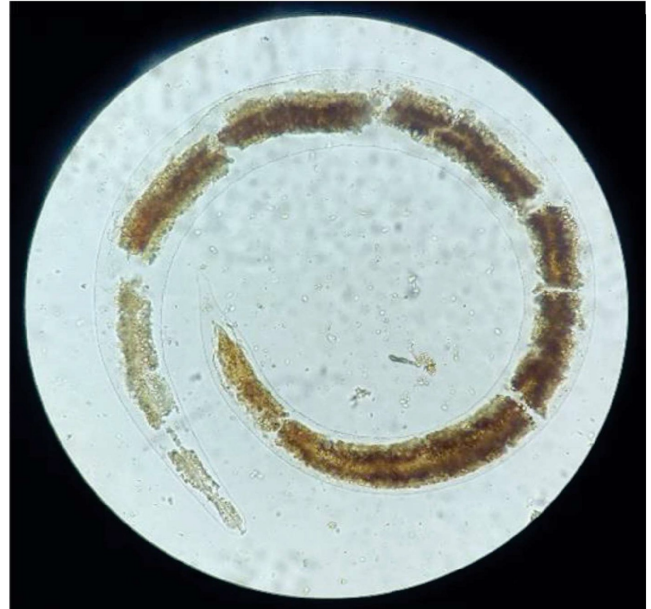**Figure 10:** Microphotograph of adult male *Aspicularis tetraptera* from *Rattus tanezumi*. Note cervical ala (red arrow), esophageal bulb (blue arrow), caudal papillae (black arrow), and absence of spicules (Unstained,400x).



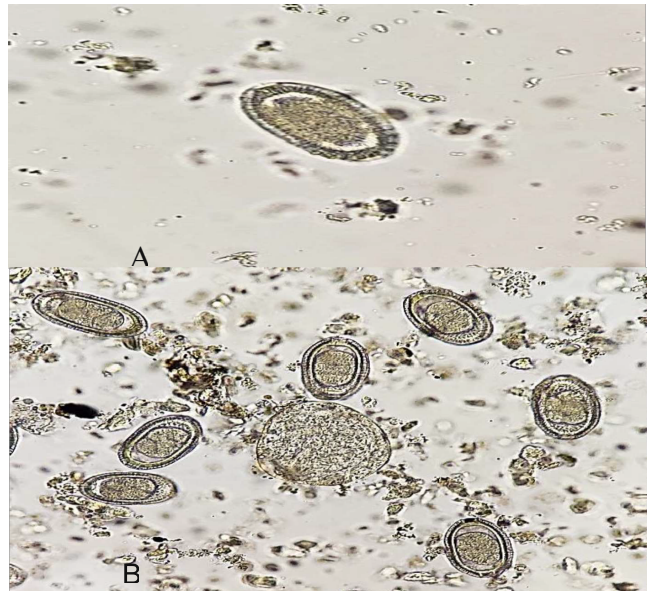
**Figure 11:** Microphotograph of the anterior region of representative *Syphacia* sp. From *Rattus norvegicus* and *R. tanezumi*. Note the absence of cervical alae (left) and the vulva located at the anterior portion of the body (arrow) (right). (Unstained, 400x).



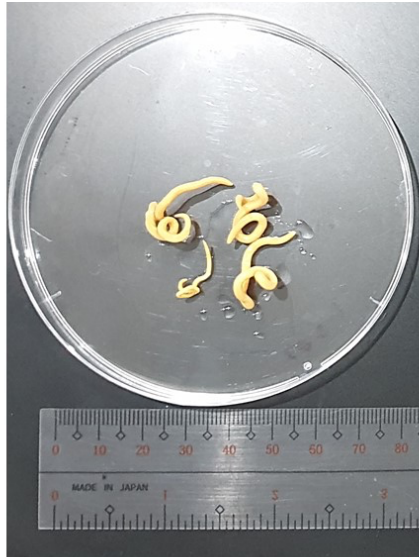
**Figure 12:** Microphotograph of the female (left: top and bottom) and male (right) adult *Nippostrongylus brasiliensis* from various *R. argentiventer* and *R. tanzumi* species. Note the presence of cuticular expansion at the anterior (black arrow), eggs (red arrow) at the posterior region of the female worm, and presence of bursa (yellow arrow) and spicule (blue arrow) at the posterior region of the male worm. (Unstained, 40x).



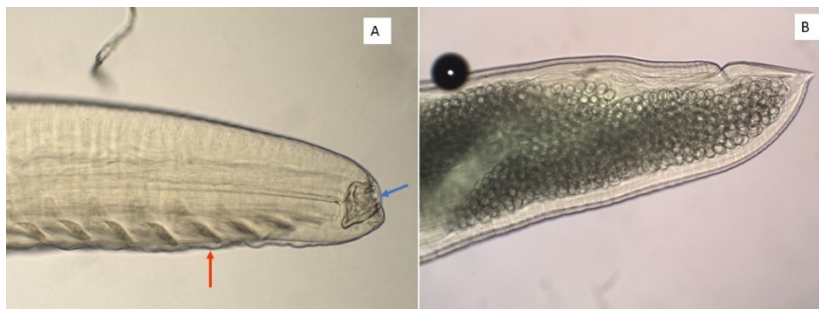**Figure 13:** Microphotograph of a *Angiostrongylus cantonensis* L1 obtained after digestion of lungs in several species of *R. argentiventer*, *R. exulans*, *R. norvegicus*, and *R. tanezumi*. (Unstained, 400x).



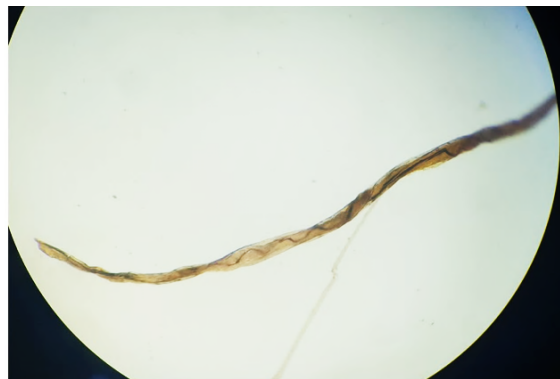**Figure 14:** Representative *Calodium hepaticum* (= *Capillaria hepatica*) ova, obtained after digestion of liver samples from several species *R. argentiventer* and *R. tanezumi*. Note that the polar plugs at both ends of the ova (yellow arrows). Are not prominent (A); *C. hepaticum* ova and *S. japonicum* ovum (B) (Unstained, 100x).



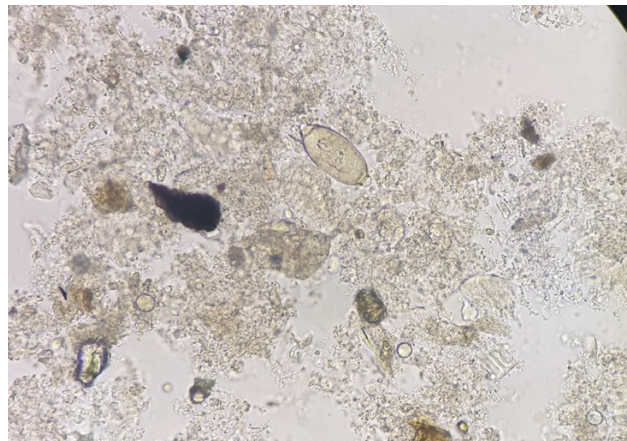
**Figure 15:** *Physaloptera* sp. adult recovered from stomach *R. norvegicus*



**Figure 16:** Microphotograph of female adult *Rictularia* sp. from *R. tanezumi* (note the buccal cavity (blue arrow) at the anterior portion (A) and the papillae (red arrow). Posterior end (B) with thick shelled egg (Lactopheno)



**Figure 17:** Microphotograph of recovered *Angiostrongylus cantonensis* adult in pulmonary artery of *Rattus exulans*



**Figure 18:** Photomicrograph of *Trichuris* sp. egg recovered from *R. argentiventer* (Note the prominent, clear polar "plugs" (or opercula) at both ends) (400x)